

First experience of left atrial appendage occlusion using a 3D mini transoesophageal echocardiographic probe with conscious sedation

Laura Sanchis, MD, PhD ; Ander Regueiro, MD, PhD ; Pedro Cepas-Guillen MD, PhD; Marta Sitges, MD, PhD ; Xavier Freixa, MD, PhD

Publication: EuroIntervention 2023 - Print January 2023

Patient History

Male, 77 years old, 55 kg LAAO with Amplatzer Amulet 20

- Duration of the intervention 40 min
- Fluoroscopy 10 min
- Duration of probe insertion 24 min

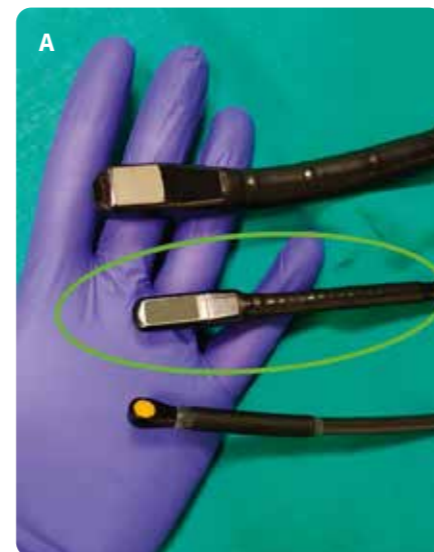Percutaneous left atrial appendage (LAA) occlusion (LAAO) is an alternative to oral anticoagulation for those patients with atrial fibrillation and a contraindication to or high risk for anticoagulation¹. LAAO procedures are typically performed with a 3D imaging technique (transoesophageal echocardiography [TOE] or computed tomography [CT]). For intraprocedural guidance, 3D-TOE is generally used, requiring general anaesthesia in most centres. Technological improvements such as the micro-TOE probe (10T-D; GE Healthcare)², allow LAAO guidance using only minimal sedation and resulting in same-day patient hospital discharge. However, micro-TOE also has limitations

(monoplane imaging, bad visualisation of the far field, need for specialised training...) which limit intraprocedural guidance in complex anatomies or inexperienced centres.

A novel mini TOE probe with 3D capabilities (9VT-D; GE HealthCare) has recently been released on the market for use in the paediatric population (Figure 1A) but with the potential to be used in adults as well. Theoretically, it will maintain the good tolerance of the micro-TOE probe while providing full 3D imaging capabilities. There are additional advantages, as compared to the micro-TOE probe, that include superior 2D imaging quality, bi-plane imaging for a safer transseptal puncture and better control during device implantation, and the possibility to perform 3D measurements for device selection during the intervention.

We present a series of the first 4 patients who underwent LAAO guided with a 3D

mini TOE probe at our centre. All patients were consecutively treated on the same day. The tolerance of the probe was excellent for all of the patients, with local oropharyngeal anaesthesia with lidocaine and minimal sedation (0.025-0.05 mg of fentanyl and 1-2 mg of midazolam – the same regimen used with the micro-TOE



probe at our centre). Imaging was good, allowing a safe transseptal puncture with bi-plane guidance and 3D measurement of the landing zone. Device sizing was based on the 3D measurements obtained during the intervention. All four procedures were successful with no residual leaks and no intraprocedural complications (mean duration of the intervention 52 min, fluoroscopy 12.5 min, radiation dose 58.1 microGy/m², TOE probe insertion 25.2 min). Only one patient (#2) required angiographic contrast administration due

to the extreme chicken wing morphology of the LAA. Figure 1B-Figure 1G and Moving image 1 show the interventional echocardiographic images during LAAO of patient #1. All patients were discharged on the same day with no complications after a 6-hr monitoring and check-up echocardiogram for pericardial effusion evaluation. Supplementary Table 1 includes patient characteristics and procedural data for all patients; Supplementary Figure 1 includes images from the interventions in patients #2-4.

The initial experience with the new 3D mini TOE probe showed good tolerance (despite minimal sedation and the supine position of the patient) with excellent imaging quality of the LAA that allowed an effective and safe LAAO guidance. The use of mini/ micro TOE probes may improve the efficiency of the catheterisation laboratory by increasing the number of patients treated per workday and allowing a safe same-day hospital discharge.

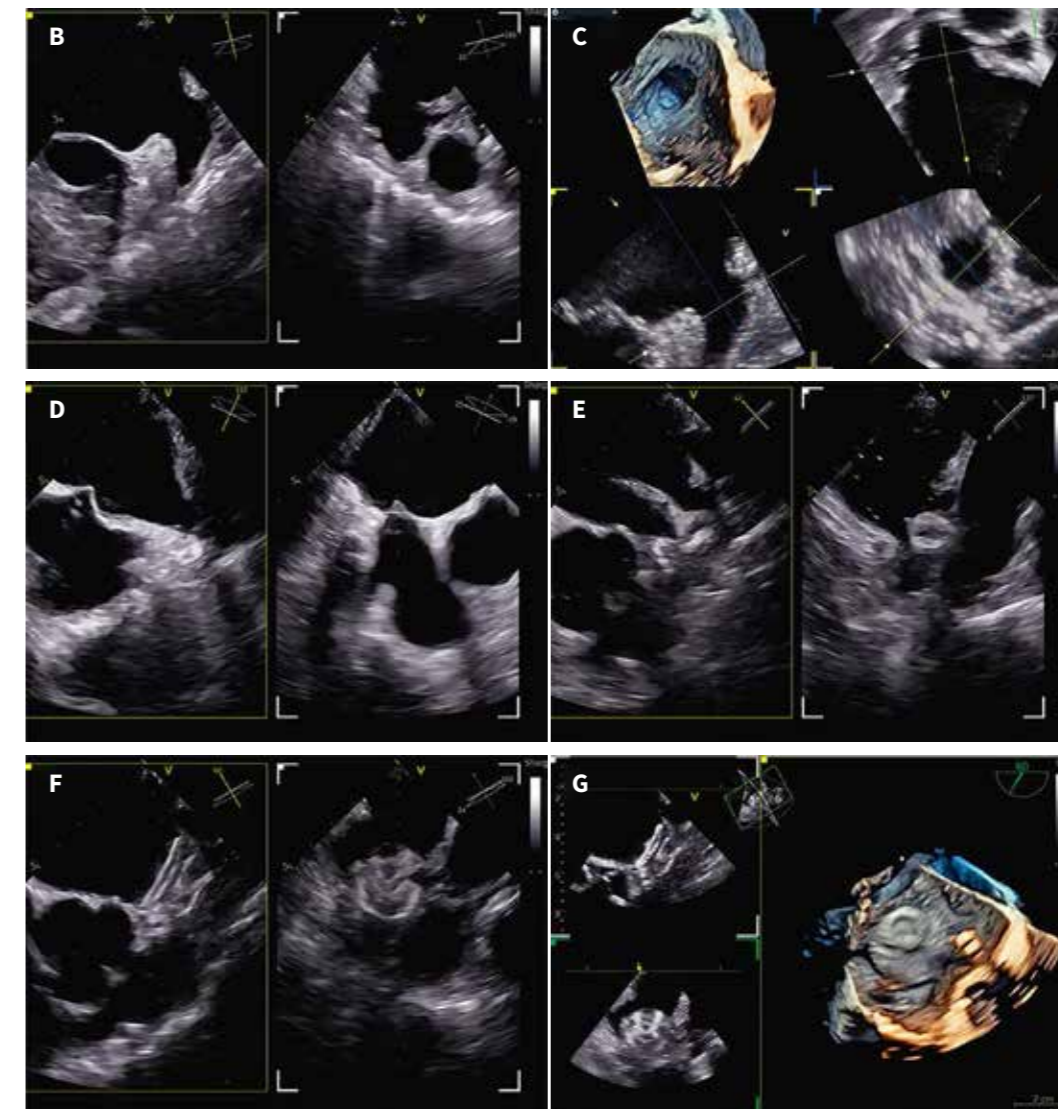
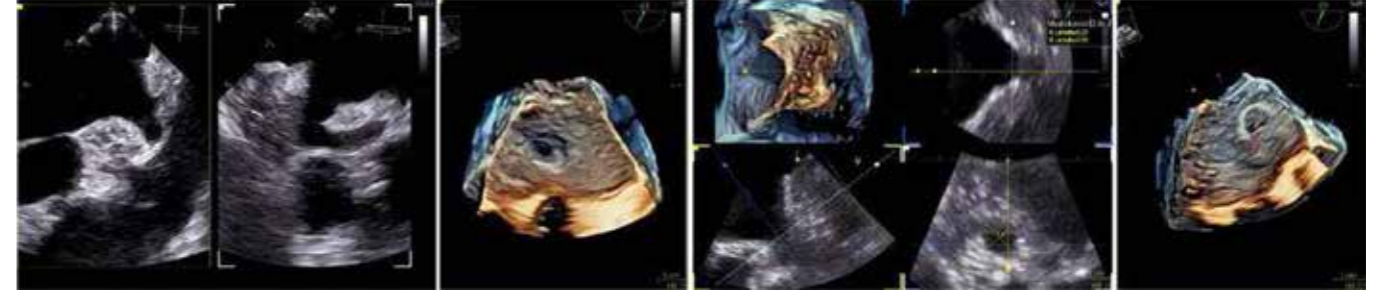

Figure 1. Interventional echocardiographic images during left atrial appendage occlusion of the first patient. A) A comparison of the mini 4D probe 9VT-D (centre, green circle) with the standard 4D probe 6VT-D (top) and the micro 2D probe 10T-D (bottom). TOE images of patient #1 during LAAO: B) LAA with bi-plane view, C) 3D LAA image with multiplanar reconstruction for landing zone measurement, D) bi-plane view for transseptal puncture with the needle inducing tenting in the septum, E) initial positioning of the device with bi-plane view, F) final position of the device with bi-plane and 3D imaging (G). 3D: three-dimensional; LAAO: left atrial appendage occlusion; TOE: transoesophageal echocardiography

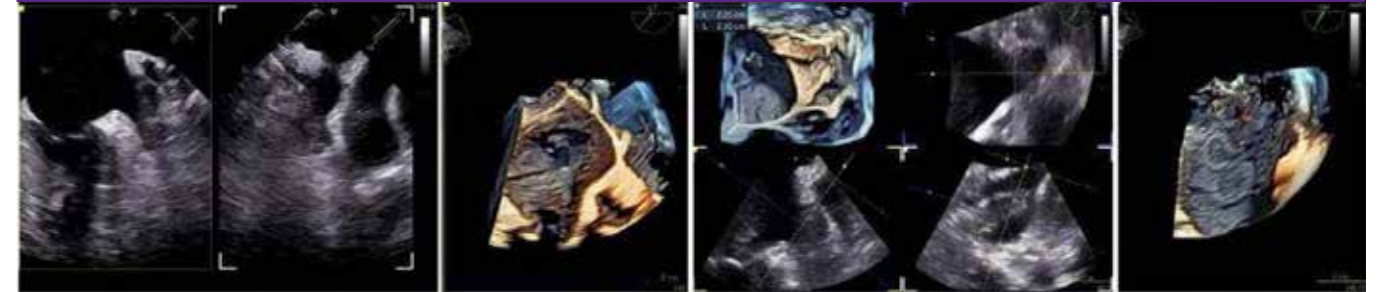Supplementary Table 1. Baseline patient characteristics and procedural data

	Patient #1	Patient #2	Patient #3	Patient #4
Sex	Male	Male	Male	Male
Age (years)	55	75	86	102
Weight (kg)	55	75	86	102
Midazolam dose (mg)	2	1.5	1	2
Fentanyl dose (mg)	0.025	0.05	0.025	0.025
Intervention duration (min)	40	61	46	60
Fluoroscopy duration (min)	10	19	5	16
Time with TEE inserted (min)	24	33	17	27
Contrast (ml)	0	60	0	0
Landing zone 3D measurement (mm)	16x15	14x13	22x21	22x18
Device	Amplatzer Amulet 20	Lambre 18/24	Amplatzer Amulet 25	Amplatzer Amulet 25

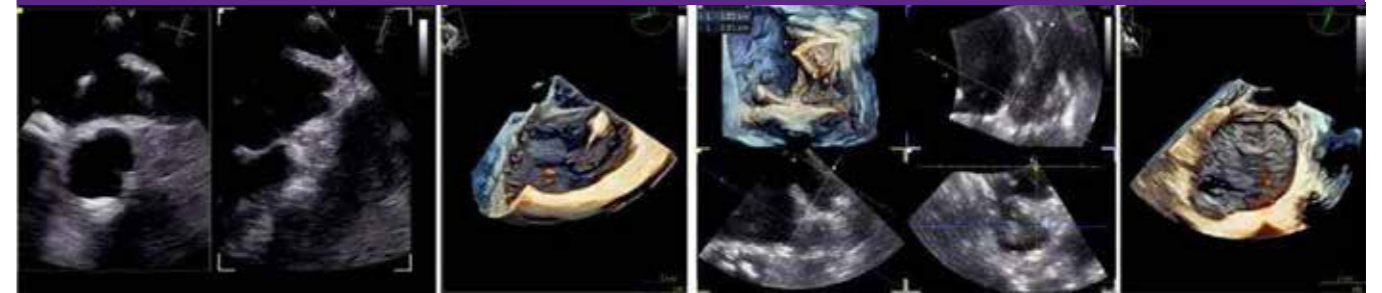Patient #2 - 67 yo, 75kg, Lambre 18x24



Patient #3 - 78 yo, 86kg, Amplatzer Amulet 25



Patient #4 - 74 yo, 102kg, Amplatzer Amulet 25



Supplementary Figure 1. Echocardiographic images from the interventions in patients #2-4.

Bi-plane view of the LAA, 3D imaging from left atrium of the ostium of LAA, 3D measurement of the landing zone with multiplanar reconstruction and final visualization with the device after deployment are shown. For patient 3, it is also included the angiographic visualization of the LAA with contrast.

Conflict of interest statement

X. Freixa is a proctor for Abbott and LifeTech Science. M. Sitges is a consultant and speaker for General Electric, Medtronic, Edwards Lifesciences, and Abbott. L. Sanchis is a proctor for Abbott and a speaker for General Electric and Abbott. The other authors have no conflicts of interest to declare regarding the present paper.

References

- Glikson M, Wolff R, Hindricks G, Mandrola J, Camm AJ, Lip GYH, Fauchier L, Betts TR, Lewalter T, Saw J, Tzikas A, Sternik L, Nietlispach F, Berti S, Sievert H, Bertog S, Meier B. EHRA/EAPCI expert consensus statement on catheter-based left atrial appendage occlusion - An update. *EuroIntervention*. 2020;15:1133-80.
- Jiménez Brítez G, Sanchis L, Regueiro A, Sabate M, Sitges M, Freixa X. Minimally-invasive Transesophageal Echocardiography for Left Atrial Appendage Occlusion With a Latest-generation Microprobe. Initial Experience. *Rev Esp Cardiol*. 2019;72: 511-2.

Supplementary data

Supplementary Table 1. Baseline patient characteristics and procedural data.

Supplementary Figure 1. Echocardiographic images from the interventions in patients #2-4.

Moving image 1. The interventional echocardiographic images during LAAO of patient #1.

The supplementary data are published online at: <https://eurointervention.pconline.com/doi/10.4244/EIJ-D-22-00921>

*Corresponding author: Cardiology Department, Hospital Clínic, C. de Villarroel 170, 08036 Barcelona, Spain. E-mail: lsanchis@clinic.cat

This paper also includes supplementary data published online at: <https://eurointervention.pconline.com/doi/10.4244/EIJ-D-22-00921>

© Europa Digital & Publishing 2023. All rights reserved.