



Elevating Coronary CT Angiography Workflow and Patient Satisfaction with Revolution CT

By *Marcello Zapparoli, MD, cardiologist; Rodrigo Julio Cerci, MD, cardiologist; Dante Luiz Escuissato, MD, PhD, radiologist; Arnolfo de Carvalho Neto, MD, PhD, radiologist; Enio Rogacheski, MD, MSc, radiologist; and Sergio Mazer MD, radiologist; Diagnóstico Avançado Por Imagem (DAPI), Curitiba, Brazil*

GE Contributors:

Caroline Bastida de Paula, Clinical Marketing Leader, and Thomas Martin Doring, PhD, Clinical Product Manager, GE Healthcare LATAM

Coronary CT Angiography (CCTA) typically requires lower heart rates and regular rhythm for optimal image quality. Oral beta-blockers are frequently used for patients with high heart rates or irregular rhythm, adding a waiting time of approximately one hour prior to the actual scan time. Avoiding the administration of a beta-blocker and associated wait time would lead to faster workflow, lower costs, shorter total exam times and increased patient convenience. With Revolution™ CT, featuring high temporal and spatial resolution, and 16 cm coverage in combination with SnapShot™ Freeze, we can significantly reduce the need for oral beta-blocker administration while achieving excellent image quality of the coronary arteries, even in patients with higher heart rates and irregular rhythm. Patients can now arrive at the clinic and go directly to the



CT scan, improving their satisfaction and comfort, and enhancing our clinical workflow.

Diagnóstico Avançado Por Imagem (DAPI) has been providing high-quality diagnostic imaging care for more than 30 years in Curitiba, Brazil, through the continuous modernization of equipment and excellence of the clinical and technical teams. The clinic acquired a Revolution CT system in 2015, which incorporates several technological developments that help deliver higher temporal and spatial resolutions.

This paper discusses our experience with Revolution CT for CCTA and provides some insight in how it changed our clinic and most importantly, our clinical workflow.

Key points

- *Patients can now arrive at the clinic and **go directly to the CT scan**, significantly elevating patient satisfaction and comfort.*
- *High temporal and spatial resolution CCTA can be achieved using Revolution CT with **significantly reduced oral betablocker administration** even in patients with high and irregular heart rates.*
- *For patient safety, radiation dose can be **reduced by 70%**, a mean of 1.5 mSv per CCTA and <1 mSv in low heart rate patients.*



Elevating performance

The number of CCTAs performed at DAPI has increased over the past decade (Figure 1). However, we experienced an exponential increase after the implementation of Revolution CT. In the last three years, we performed approximately 4,600 CCTAs with Revolution CT compared to the 5,400 CCTAs performed in the seven years prior, using both 64- and 128-slice CT scanners from other manufacturers. After the acquisition of Revolution CT, nearly all CCTAs were done on the new system and we were able to accommodate a 212% increase in the number of CCTA studies performed each year, from an average of 721 exams/year to 1,533/year (Figure 2).

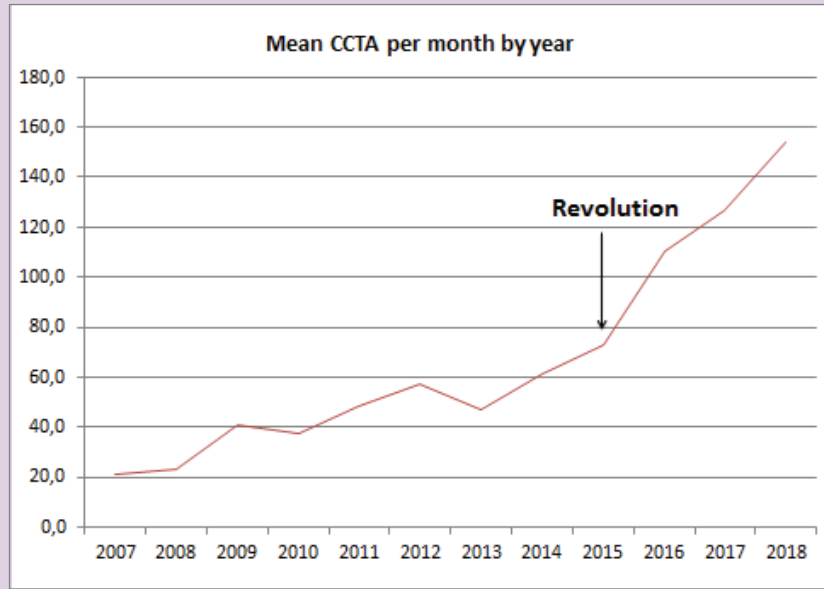


Figure 1. Mean number of CCTA scans per month by year at DAPI. Revolution CT was installed in October 2015.

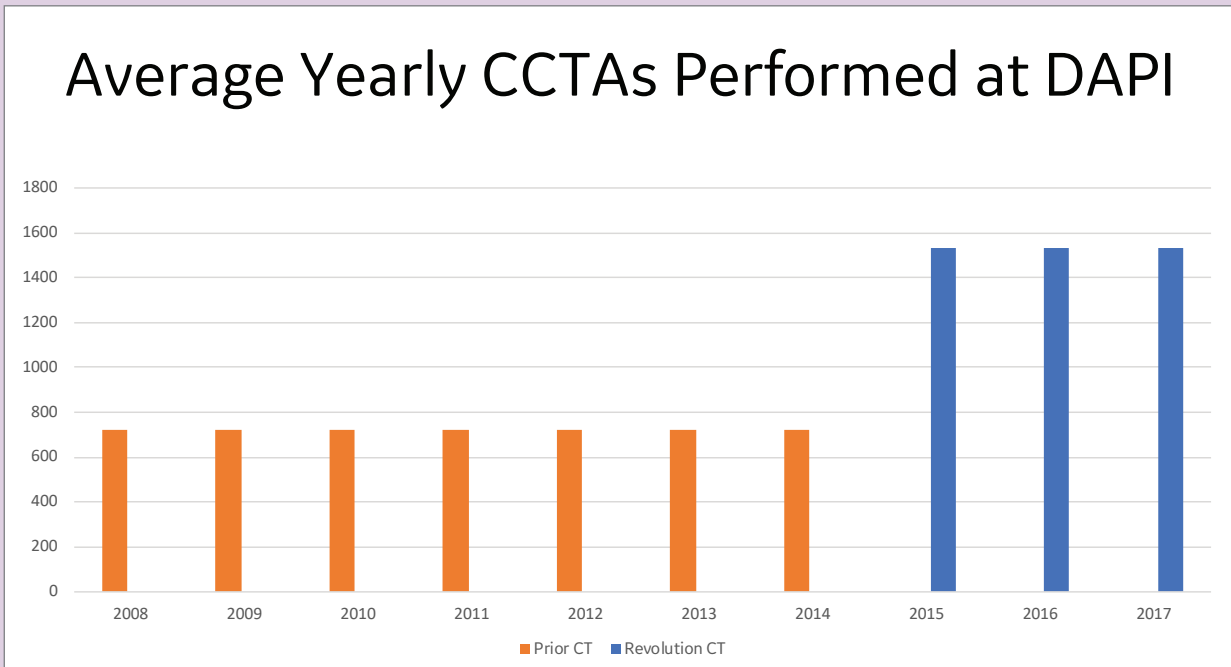


Figure 2. Shows increase in patient throughput using Revolution CT compared to the prior scanners.



Patient experience

The capability to achieve an extreme high temporal resolution of 140 ms (0.28 s/rotation) with Revolution CT along with using SnapShot Freeze for intelligent motion correction technology that allows for 24 ms effective cardiac temporal resolution, we can now perform CCTAs on the more challenging patients that present with high heart rates or irregular rhythm. In our experience, prior to the acquisition of Revolution CT we had to achieve a target heart rate (HR) of ≤ 60 beats per minute (bpm) to obtain images with sufficient diagnostic quality. A patient who presented with a heart rate of ≥ 70 bpm needed oral beta-blocker (oral BB) administration that **required a one hour waiting time to take effect**. Patients with a HR between 60 and 70 bpm were submitted to intravenous beta-blocker (intravenous BB) administration to achieve the target frequency (≤ 60 bpm).

After installing Revolution CT this strategy has changed. Independent of the initial heart rate upon arrival, the patient is taken directly to the CCTA scan without oral BB administration. The target HR is no longer limited to 60 bpm or lower and we can successfully scan patients with up to 70 bpm while achieving an excellent diastolic reconstruction. For systolic reconstruction the HR can be up to 80 bpm and in some cases, higher.

Due to the success of high HR studies on Revolution CT, we abolished oral BB administration, therefore, **eliminating the one hour waiting time**, and only use intravenous BB to a fine adjustment. In patients with irregular rhythm, ranging from simple extra systoles to more challenging arrhythmias like atrial fibrillation, the strategy now involves a prospective acquisition within one heart beat and,

if needed, automatically acquire a second one heart beat shot within the same contrast injection. This has made it possible to obtain excellent images even in these challenging situations. Patient satisfaction and comfort have also significantly improved, as they can now arrive at the clinic and go directly to the CT system for a CCTA study.

Technical Highlights Revolution CT

- *Revolution CT features Volume HD reconstruction and next generation ASiR-V™ technology to enable excellent image quality across the entire 160 mm coverage, while significantly reducing dose.*
- *Gemstone™ Clarity Detector delivers 160 mm detector coverage and enables high definition imaging and ultra-fast kV switching.*
- *New tube for improved spatial resolution and consistent beam quality across the full 160 mm Z-axis coverage.*
- *Effective temporal resolution enabled by 0.28-second rotation speed combined with intelligent motion correction for excellent cardiac imaging at any heart rate.*
- *Miniaturized detector modules are designed to reduce electronic noise by 25%, which may improve image quality and reduce artifacts in low signal conditions, as may be encountered in large patients.*
- *Unique focally aligned detector design to overcome limitations such as cone beam artifacts associated with wide coverage.*
- *Proprietary 3D collimator ensures IV contrast uniformity and minimizes scatter and beam hardening artifacts associated with wide coverage systems. It reduces scatter by more than 50% compared to a 160 mm system with a one-dimensional post patient collimator.*
- *Whisper Drive system reduces audible noise during gantry rotations by more than 50%.*
- *Contactless slip ring transfers data to and from the rotating side of the gantry to the stationary side through RF technology at 40 Gbps. Induction based, brushless slip ring reliably transfers high voltage power.*



Case report

Patient history

A 70-year-old female patient with atypical chest pain, hypertension and dyslipidaemia was referred for CCTA after a positive treadmill stress test. Patient was **contraindicated for betablocker** due to severe chronic obstructive pulmonary disease (COPD).

Acquisition Protocol	
Tube voltage [kV]	120
Tube current [mAs/rot]	475
Dose modulation	Smart mA
Scan length [mm]	140
Scan direction	Craniocaudal
Scan time [s]	0.28
Slice collimation [mm]	160x0.625
Recon Increment	0.6
Slice width [mm]	0.625
Heart rate [bpm]	102
Recon kernel	Standard / ASIR 70
Contrast [mg/mL]	370
flow rate [mL/s]	5
start delay	Smart Prep
Volume [mL]	65

Table 1. CT acquisition protocol.

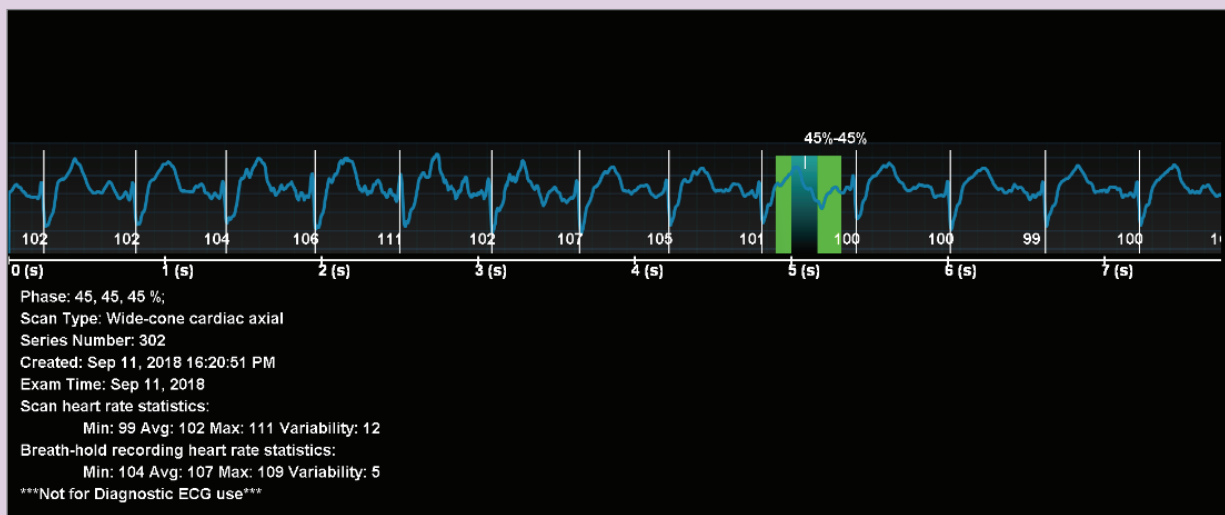


Figure 3. Patient presenting with high heart rates during CCTA scan (99 bpm - 111 bpm, avg. 102 bpm).



Dose Report					
Series	Type	Scan Range (mm)	CTDIvol (mGy)	DLP (mGy*cm)	Phantom cm
SCOUT					
1	Scout	S0-I400	0.06	2.27	Body 32
1	Scout	S0-I400	0.06	2.27	Body 32
CALCIUM SCORE					
2	Axial	I135.125-I292.625	2.57	41.12	Body 32
ANGIO					
3	Axial	I138.812-I278.188	7.02	98.33	Body 32
201	SmartPrep	I150-I150	1.42	0.71	Body 32

Table 2. Dose report for the CCTA scan of the patient. Radiation dose was 1.37 mSv.

CT findings

Non-obstructive calcified atherosclerosis on the left main, circumflex and right coronary artery. A questionable right coronary artery ostial lesion was excluded with SnapShot Freeze reconstruction (Figure 4). Non-calcified, mid-left anterior descending artery atherosclerotic plaque with positive remodelling, also non-obstructive but best evaluated with SnapShot Freeze reconstruction (Figure 6). ■

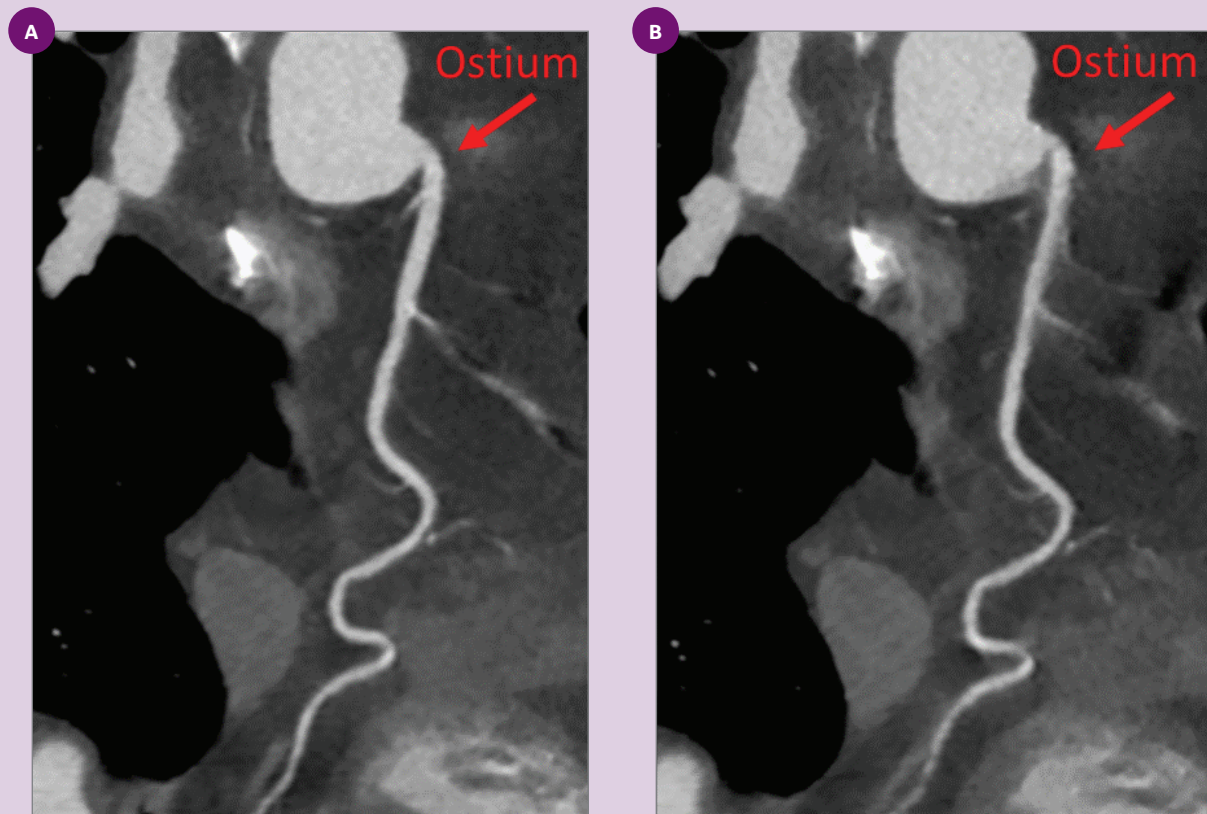


Figure 4. Images of the right coronary artery (A) **with** SnapShot Freeze and (B) **without** SnapShot Freeze.

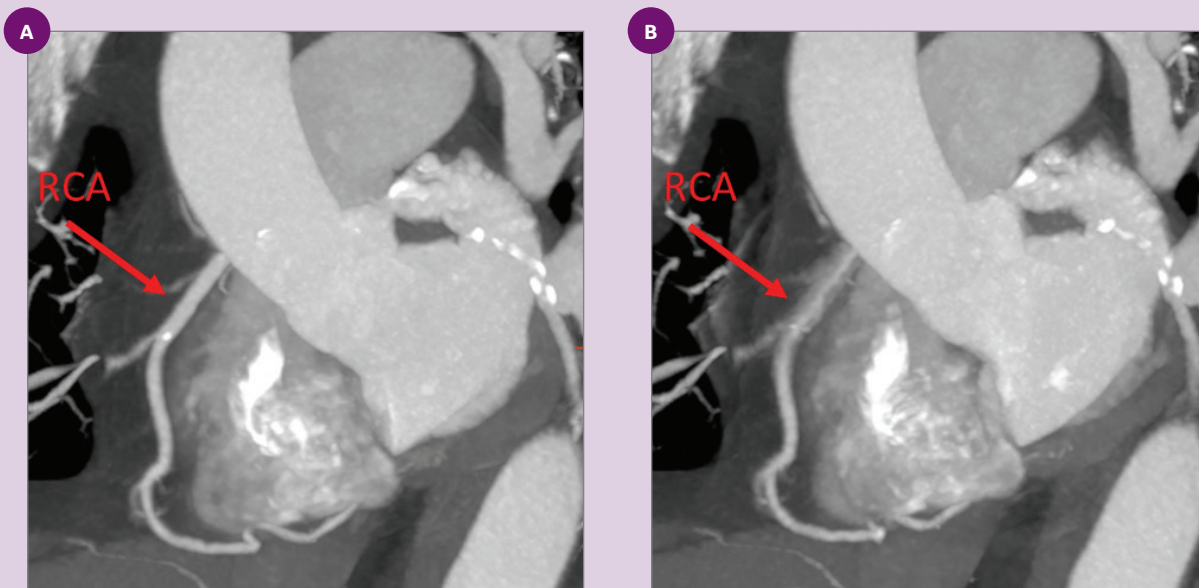


Figure 5. Reconstruction (A) **with** SnapShot Freeze, showing RCA without motion artifact, and (B) **without** SnapShot Freeze, presenting motion artifact.

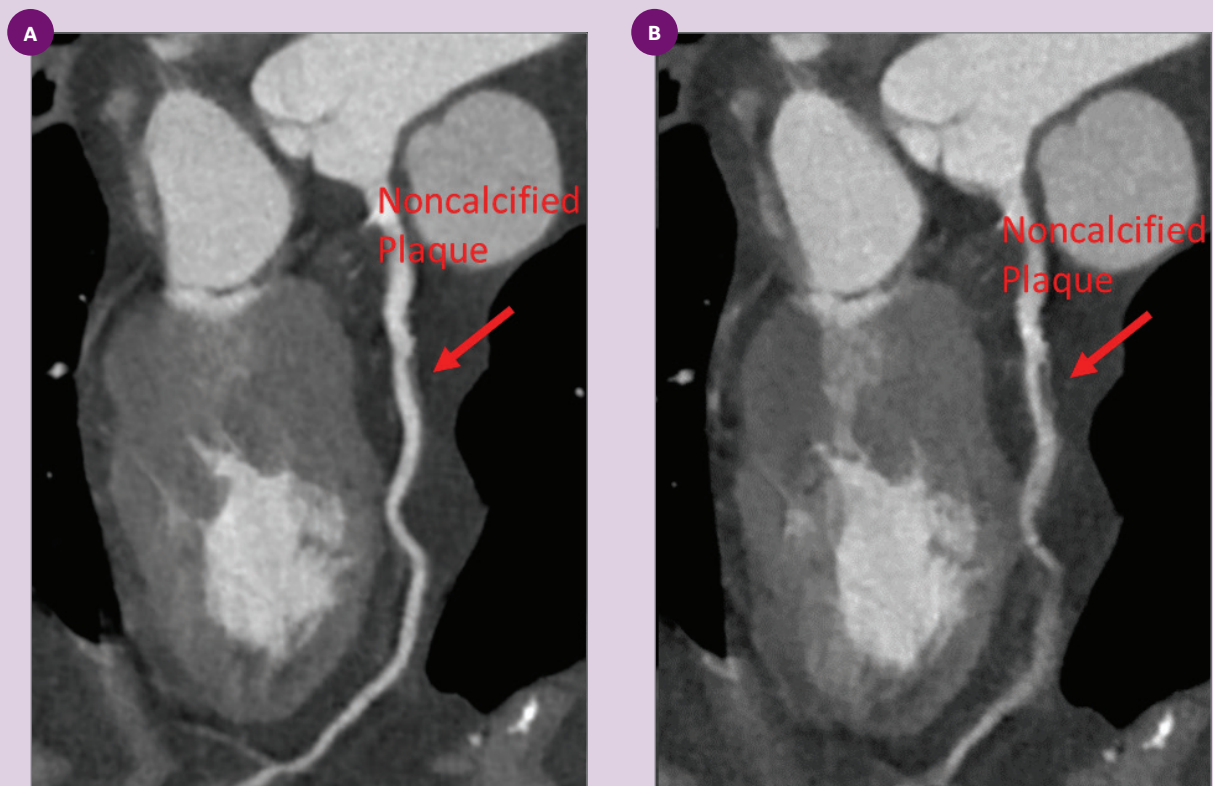


Figure 6. Left descending artery (A) **with** SnapShot Freeze and (B) **without** SnapShot Freeze showing a non-calcified plaque.

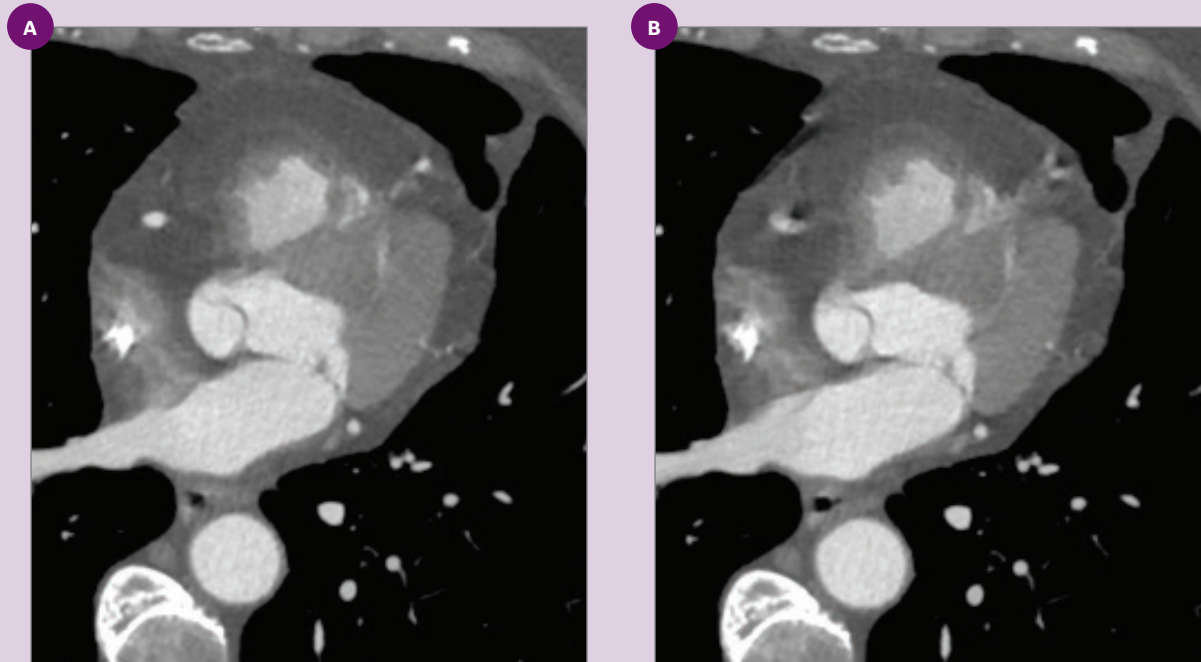


Figure 7. Axial slice (A) **with** SnapShot Freeze and (B) **without** SnapShot Freeze.

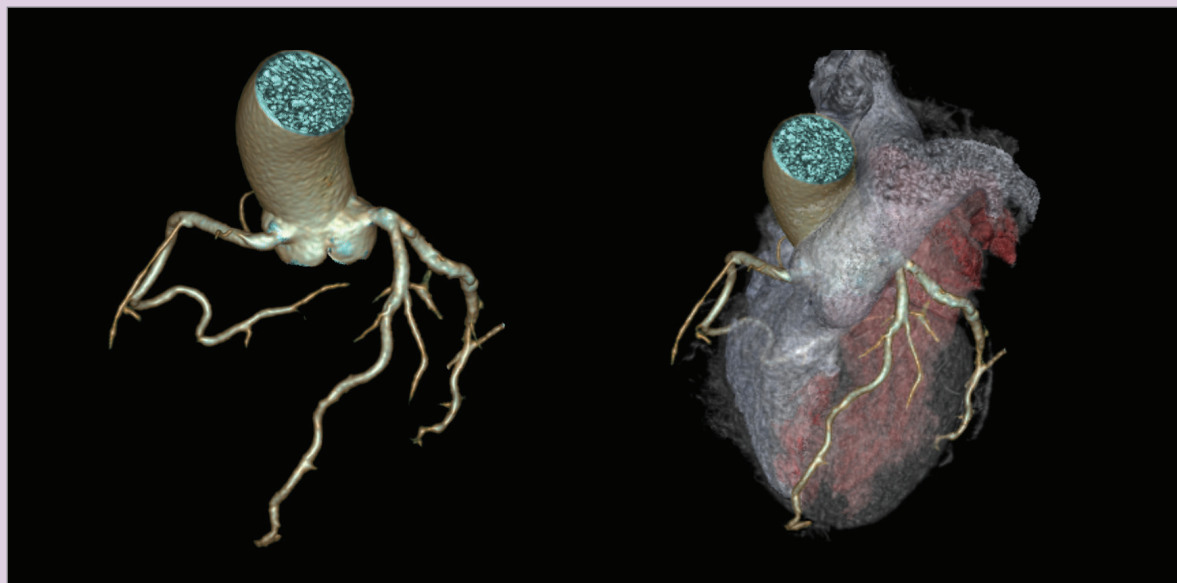


Figure 8. Volume rendered images (VRT) of the patient's heart.



GE Healthcare

© 2018 General Electric Company — All rights reserved.

General Electric Company reserves the right to make changes in specification and features shown herein, or discontinue the product described at any time without notice or obligation. The products/technologies mentioned in this material could be subject to government legislation. The importation and commercialization of it will only occur after regulatory approval. The products/technologies could be described with their market names, different from what is approved in the regulator. The commercialization of it will occur with the product name registered in the regulator.

GE, ASiR-V, Gemstone, Revolution and SnapShot are trademarks of General Electric Company.

GE Healthcare, a division of General Electric Company.

JB63407BR